

Vascular Injuries

Introduction

- History.
 - **World War II:** Popliteal artery injuries were routinely ligated and associated with a 73% amputation rate.
 - **Korean War:** Formal repair of peripheral arterial injuries instituted.
 - **Vietnam War:** Further refinements in arterial repair; amputation rate for popliteal artery injuries is reduced to 32%.
 - **Iraq and Afghanistan:** Forward Role 2 care refines use of temporary vascular shunts, and Joint Theater Trauma System (JTTS) advances recoding of injury.
- There are various types of wounds seen in combat.
 - Low-velocity missile/fragment damages a blood vessel lying directly in its path.
 - High-velocity missile/fragment wounds with blast causes widespread damage, including vascular injury at a distance (remote injury).
 - Blunt trauma, often resulting from sudden deceleration in motor vehicle accidents, falls, and rail and air disasters.
 - Popliteal artery injury associated with posterior knee dislocations.

Epidemiology of Vascular Injury

- 1 in 5 (20%) battle injuries (nonreturn to duty) is coded with hemorrhage control not otherwise specified.
- Rate of vascular injury in modern combat is 12%, which is higher than the 1%–3% reported in World War II, Korea, and Vietnam. Rate of operative vascular injury is 9%, with half being ligations and half requiring repair.

- Extremity vessels account for 70%–80% of vascular injuries, whereas 10%–15% are in the cervical region and 5%–10% are in the torso.

Roles of Care and the Management of Vascular Injury

Each role has unique approaches to the management of vascular injury:

- **Role 1.**
 - Hemorrhage control (direct pressure, tourniquet, or topical hemostatic agent) and other life-saving interventions/evacuation.
- **Role 2.**
 - Operations at forward operating locations are abbreviated (preferably <1 hour).
 - Intervention on extremity vascular injury is important and may make the difference in meaningful limb salvage.
 - Primary amputation or ligation is also an acceptable damage control technique when other life-threatening injuries are present.
 - If limb salvage is to be attempted, tourniquet removal, exploration and control of vascular injury, thrombectomy, and administration of heparinized saline through the inflow and outflow vessels are recommended.
 - Restoration of flow can then be established using a temporary vascular shunt followed by fasciotomy and MEDEVAC (medical evacuation). Definitive repair at this level can be considered with caution, depending on available equipment and the tactical situation.
- **Role 3.**
 - Removal of tourniquet(s) and temporary vascular shunts placed as forward locations followed by definitive vascular repair.
 - Saphenous vein is preferred as a conduit for extremity vascular injuries.
 - Extremity evaluation will be difficult during AIR EVAC (air evacuation) out of theater, and Role 3 must ensure adequacy of perfusion, fasciotomy, and debridement.

- Primary amputation or ligation is acceptable damage control technique when other life-threatening injuries are present.
- **Role 4 (Safe Haven).**
 - Surveillance of repair, including an assessment of soft-tissue wounds and tissue coverage prior to continuing AIR EVAC.
- **Role 4 (CONUS).**
 - Surveillance of vascular repair with duplex or CTA (computed tomography angiography) and assessment of soft-tissue wounds and adequacy of tissue coverage.
 - Revision of repairs with stenosis or inadequate tissue coverage leaving them prone to infection and blowout.
 - Delayed revascularization of viable, but poorly perfused, extremities in which ligation was chosen as the initial method of care.

Evaluation and Diagnosis

- **Hard signs.**
 - Active hemorrhage or expanding hematoma.
 - Bruit or thrill.
 - Ischemia—defined as the absence of Doppler signal in the extremity on multiple attempts over time after resuscitation—warming, and reduction of fractures.
 - Hard signs require management in the operating room with wide exposure and exploration of the injury (ie, control of vascular injury). Unlike civilian vascular trauma, there can be multiple injuries in a single vessel.
 - There is limited need for other diagnostic tests (ie, CTA or angiography) that take time and often provide unclear findings.
- **Soft signs.**
 - Proximity to vessel, fracture/injury pattern (eg, knee dislocation), hematoma, or question regarding palpable pulse.
 - Often require another diagnostic test, such as continuous wave Doppler with or without calculation of the injured extremity index.
 - CTA or angiography is useful as a diagnostic adjunct in the presence of soft signs of vascular injury.

- The injured extremity index.
 - Similar to the ankle–brachial index and is calculated using a manual blood pressure cuff and a continuous wave Doppler.
 - First step is to determine the pressure at which the arterial Doppler signal occludes in the injured extremity (numerator).
 - Cuff and Doppler moved to uninjured extremity and occlusion pressure of Doppler signal recorded (denominator).
 - Injured extremity index >0.90 is normal and has a high specificity for excluding extremity vascular injury in the absence of hard signs.
- Angiography.
 - Limited utility in the diagnosis of wartime extremity vascular injury and, in the presence of hard signs, preference is given to incision and exposure of segment in question.
 - Limitations related to the availability and quality of imaging technology in austere environments.
 - Extremity vasoconstriction with shock and hypothermia in young troops may lead to confusing or false-positive findings.
 - Angiography has the greatest utility in the setting of multiple penetrating wounds at various levels of the same extremity.
 - Angiography may be done via cut down using a small gauge needle or catheter to inject contrast minimizing complications.
 - Advantage to angio is its low volume of contrast, especially useful in patients at risk for renal failure.
- CTA.
 - Increasingly available in a mature theater of war and has the greatest utility in the diagnosis and triage of torso and neck wounds.
 - CTA is often used as a screening tool for suspected vascular injury.
 - This modality takes additional time, contrast, and technical experience to provide accurate and meaningful images.

Management Aspects: Extremity Vascular Injury

Upper Extremity

Consider prophylactic distal fasciotomies in all patients with prolonged ischemia times.

- **Subclavian artery.**
 - Recommendations: Shunt or ligate as damage control, or definitive repair.
 - Utility of temporary shunt: High, but difficult due to technical difficulty of exposure and placement.
 - Method/conduit: Interposition graft/6–8 mm ePTFE (expanded polytetrafluoroethylene) or Dacron.
 - Pearls:
 - ◆ Proximal subclavian vessels and innominate are approached through a median sternotomy.
 - ◆ Alternatively, a proximal left subclavian artery can be approached using a high (third intercostal space) anterolateral thoracotomy supraclavicular approach through the clavicular head of the sternocleidomastoid, sternothyroid/hyoid muscles to the scalene fat pad with retraction of the phrenic nerve, and division of the anterior scalene; may resect the clavicular head.
 - ◆ The mid- and distal subclavian arteries on both sides can be exposed through combination supra- and infraclavicular incisions.
 - ◆ Avoid injury to the phrenic nerve, internal mammary, thyrocervical, and vertebral arteries.
- **Axillary artery.**
 - Recommendations: Shunt or ligate as damage control, or definitive repair.
 - Utility of temporary shunt: High.
 - Method/conduit: Interposition graft/reversed saphenous vein.
 - Pearls:
 - ◆ Supra- and infraclavicular incisions allow proximal control and distal exposure.

- ◆ Prep axilla, arm, and hand into operative field.
- ◆ Infraclavicular exposure includes division of the clavipectoral fascia and the pectoralis major muscle.
- ◆ The proximal axillary artery is then visible under the pectoralis minor muscle, which can be retracted laterally or divided.
- ◆ Avoid the brachial plexus, which will be deep or lateral to the axillary artery.
- **Brachial artery.**
 - Recommendations: Shunt or ligate as damage control, or definitive repair.
 - Utility of temporary shunt: High.
 - Method/conduit: Interposition graft/reversed saphenous vein.
 - Pearls:
 - ◆ Medial approach; adjacent to the median nerve in brachial sheath in biceps/triceps groove.
 - ◆ Elastic artery with redundancy; flex arm slightly for interposition grafts to avoid kinking.
 - ◆ Ligation may be tolerated if collaterals are intact.
- **Radial/ulnar arteries.**
 - Recommendations: Selective repair (maintain at least one vessel flow to hand).
 - Utility of temporary shunt: Low patency rate.
 - Method/conduit: Ligation or interposition graft/reversed saphenous vein.
 - Pearls:
 - ◆ Perfusion to the hand should be assessed with Doppler before and after occlusion or ligation.
 - ◆ The presence of an arterial Doppler signal in the hand obviates the need for arterial repair. Repair with saphenous vein in instances where there is persistent absence of an arterial signal.
 - ◆ The majority of individuals have ulnar-dominant perfusion; when possible, repair/reconstruct the ulnar artery.

Lower Extremity

Consider prophylactic distal fasciotomies in all injuries with prolonged ischemia times.

- **Common femoral artery.**

- Recommendations: Shunt as damage control or definitive repair.
- Utility of temporary shunt: High.
- Method/conduit: Interposition graft/saphenous vein or 6–8 mm prosthetic.
- Pearls:
 - ◆ Injury to the common femoral artery is often fatal because hemorrhage control in the field is difficult.
 - ◆ Expose artery at the inguinal ligament for proximal control (2–3 cm lateral to the pubic tubercle) (Fig. 25-1).

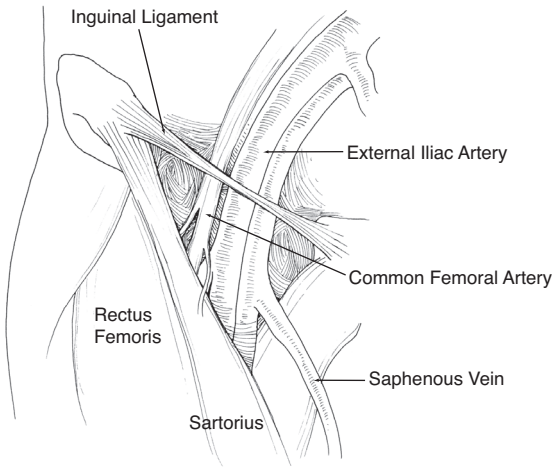


Fig. 25-1. Inguinal anatomy.

- ◆ Proximal control can be obtained in the retroperitoneum (ie, external iliac) through the proximal extension of this groin incision or by using an incision in the lower abdomen.
- ◆ Attempt to maintain flow in the profunda femorus artery. Cover with tissue (femoral sheath), the sartorius muscle, or the rectus flap (Role 4).
- Profunda femorus artery.
 - Recommendations: Selective repair.
 - Utility of temporary shunts: Low due to difficult exposure.

- Method/conduit: Ligation or interposition graft/saphenous vein.
- Pearls:
 - ◆ Exposure of proximal profunda is the same (distal extension) as the common femoral.
 - ◆ If superficial femoral is injured, repair of the profunda is necessary to heal amputations.
 - ◆ If superficial femoral is patent, ligation of mid- to distal profunda injuries is acceptable.
 - ◆ Proximal profunda injuries should be repaired with reversed saphenous vein interposition.
- Superficial femoral artery.
 - Recommendations: Shunt as damage control or definitive repair.
 - Utility of temporary shunts: High.
 - Method/conduit: Interposition graft/reversed saphenous vein.
 - Pearls:
 - ◆ Medial incision with “bump” under calf.
 - ◆ Exposure of the proximal $\frac{1}{3}$ below the sartorius and distal $\frac{1}{3}$ above the sartorius.
 - ◆ Be wary of the adjacent vein (may be adherent to artery) and geniculate branches at the distal artery (Hunter’s canal).
- Popliteal artery.
 - Recommendations: Shunt as damage control or definitive repair.
 - Utility of temporary vascular shunts: High.
 - Conduit: Reversed saphenous vein.
 - Pearls:
 - ◆ Medial incision with “bump” under calf for above knee and under thigh for below knee.
 - ◆ Natural dissection planes exist in exposing the above-knee popliteal artery (ie, popliteal space) with the exception of the need to divide the fibers of the adductor magnus that envelopes the distal superficial femoral artery (Hunter’s canal) (Fig. 25-2).
 - ◆ To completely expose the popliteal space, the medial attachments of the sartorius, semitendinosus, semimembranosus, and gracilis to the medial condyle

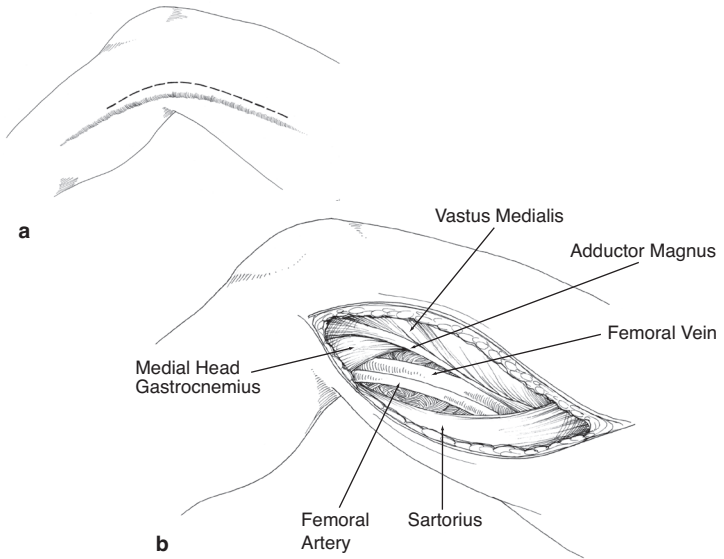


Fig. 25-2. Exposure of distal femoral and popliteal vessels.

of the tibia can be divided. Distal exposure by division of the gastrocnemius and soleus from the tibia allows dissection to the anterior tibial origin and the tibial-peroneal trunk. Extraanatomical bypass can also be performed without the need to expose the injured segment (Figs. 25-3 and 25-4).

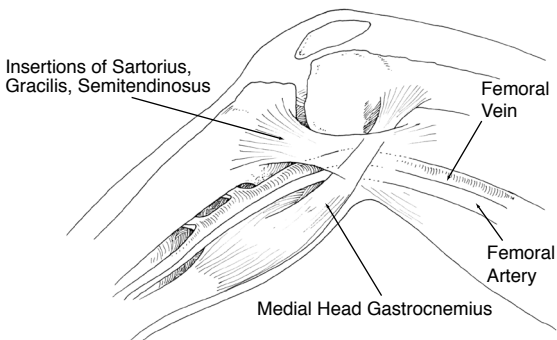


Fig. 25-3. Medial approach to popliteal vessels.

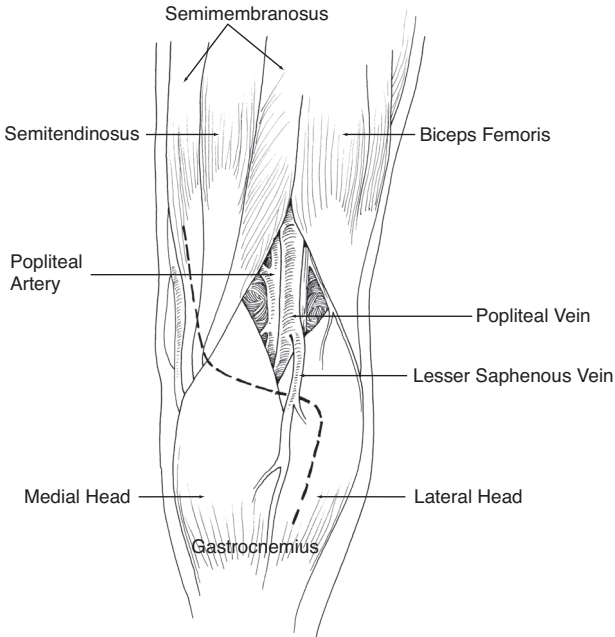


Fig. 25-4. Posterior approach to popliteal vessels.

● **Tibial arteries.**

- Recommendations: Selective repair.
- Utility of temporary vascular shunts: Low due to difficult exposure, small caliber, and low patency rates.
- Method/conduit: Ligation or interposition graft with saphenous vein.
- Pearls:
 - ◆ If a Doppler signal is present at the ankle, indicating that one or more tibial arteries are patent, there is no need for additional tests or repair.
 - ◆ Doppler exam should be repeated as patient is resuscitated and warmed.
 - ◆ Exposure of the posterior tibial artery in the deep compartment of the leg is through a medial incision with a lift or “bump” under the knee or thigh. Repair with vein if three tibial arteries are injured and an absence of a Doppler signal persists.

- **Extremity venous injury.**
 - Recommendations: Selective repair.
 - Utility of temporary vascular shunts: Moderate for large vessels.
 - Method / conduit: Ligation, repair, or saphenous interposition graft.
 - Pearls:
 - ◆ Repair of proximal veins is indicated to reduce venous hypertension and congestion.
 - ◆ Shunts in proximal veins will usually remain patent until formal repair can be performed.
 - ◆ Techniques of lateral venorrhaphy are acceptable, although patch angioplasty or an interposition graft using saphenous vein from the uninjured limb is often necessary.
 - ◆ Consider removing thrombus from the distal venous segments with compression (eg, ACE wrap or Esmark bandage) prior to repair.
 - ◆ Pneumatic compression device on distal extremity to augment venous flow after repair.
 - ◆ Limb salvage benefit of vein repair compared with ligation has been shown 2 years after injury.
 - ◆ Repair of extremity venous injury should only be considered in stable patients.

Management Aspects: Torso Vascular Injury

- **Aorta.**
 - Pearls:
 - ◆ With small penetrating injuries to the aorta of the chest or abdomen, primary repair can be attempted.
 - ◆ When not amenable to repair, a shunt can be placed (eg, chest tube).
 - ◆ Recognize that penetrating injury may involve entrance and exit wounds to the aorta that may not be obvious.
 - ◆ Management of *penetrating injury* to the aorta is very rare, given the prehospital lethality of this injury.
 - ◆ Management of *blunt injury* to the thoracic aorta (partial transection or pseudoaneurysm) is rare.

- ◆ Most survivors can be managed medically with control of heart rate and blood pressure using beta-blockers and permissive hypotension.
- ◆ Endovascular repair can be attempted at some Role 3 facilities.
- Vena cava.
 - Pearls:
 - ◆ Establish resuscitation lines above the diaphragm for abdominal vena cava injuries.
 - ◆ Vena cava injuries should be exposed using the Cattell-Braasch and Kocher maneuvers.
 - ◆ Lateral repair is acceptable, understanding that the lumen may be compromised.
 - ◆ If occlusion of the cava results in hypotension, clamp aorta to support central perfusion.
 - ◆ Retrohepatic and retroperitoneal hematomas should not be disturbed if not actively bleeding or expanding.
 - ◆ Attempt to identify large lumbar veins feeding the injured segment that can bleed profusely.
 - ◆ Patch angioplasty or resection and interposition graft using ePTFE are reconstructive options.
 - ◆ Ligation of the cava is acceptable as a damage control maneuver. If air transport is going to be utilized, then prophylactic bilateral lower extremity fasciotomies should be performed.
- **Portal vein and hepatic artery.**
 - Pearls:
 - ◆ Pringle maneuver should precede exploration of the portal triad.
 - ◆ Ligation of hepatic artery injuries is acceptable, if the portal vein is patent.
 - ◆ Lateral venorrhaphy is preferred.
 - ◆ Damage control ligation of the portal vein is an option; it results in hepatic ischemia, splanchnic congestion, and systemic hypovolemia.
 - ◆ Cholangiography through the gallbladder or with a small butterfly needle in the common bile duct should be considered in order to look for associated injuries of the extrahepatic biliary system.

- **Mesenteric arteries.**

- Pearls:
 - ◆ Present as supramesocolic zone I hematoma.
 - ◆ Repair proximal mesenteric artery and vein injuries, including portal vein.
 - ◆ Repair options: primary pledgeted repair, vein patch angioplasty, or replacement of the injured segment with interposition saphenous vein graft.
 - ◆ Ligation can be performed for distal artery and vein injuries or as damage control.

- **Renal arteries.**

- Pearls:
 - ◆ Explore zone II expanding hematomas from penetrating injury; 90% of explored kidneys result in nephrectomy.
 - ◆ Establish status of contralateral kidney by contrast study or manual palpation prior to nephrectomy.
 - ◆ Damage control may require early nephrectomy. Devascularized kidney that is not bleeding may be left in situ.

- **Iliac arteries.**

- Recommendations: Ligate or shunt as damage control, or definitive repair.
- Utility of temporary vascular shunts: High.
- Method/conduit: Interposition graft/ePTFE or Dacron or saphenous vein.
- Pearls:
 - ◆ Explore zone III hematoma from penetrating wound after establishing aortic control.
 - ◆ Distal control is obtained at the inguinal ligament (for external iliac arteries).
 - ◆ If there is primary injury to, or back bleeding from the internal iliac artery (hypogastric), it may be ligated. Try to avoid ligating both internal iliacs due to risk of gluteal ischemia/necrosis.

Management Aspects: Cervical Vascular Injury

- **Carotid artery.**

- Recommendations: Ligate or shunt as damage control, or definitive repair.

- Utility of temporary vascular shunts: High.
- Method/conduit: Vein patch or vein interposition graft.
- Pearls:
 - ◆ Zone I injuries best approached with median sternotomy for ample proximal exposure.
 - ◆ Early control of common carotid.
 - ◆ 3 Fr Fogarty catheter with three-way stopcock is useful to occlude internal carotid back bleeding.
 - ◆ During carotid repair consider temporary shunt and augmentation of mean arterial pressure.
 - ◆ CTA aids in the triage for urgent operation, improves operative planning, and images the brain as a baseline.
 - ◆ A selective approach to exploration of zone II neck wounds is acceptable in a patient without hard signs of vascular injury or aerodigestive involvement.
 - ◆ Penetrating neck wounds that are not selected for exploration should undergo CTA to further evaluate **for vascular, tracheal, or esophageal injury**.
 - ◆ Exposure of the carotid artery is through a standard anterior sternocleidomastoid neck incision.
- **Vertebral artery.**
 - Recommendations: Ligate.
 - Utility of temporary vascular shunts: None.
 - Method/conduit: Not applicable.
 - Pearls:
 - ◆ Bleeding vertebral artery injuries are ligated with no role for reconstruction in theater.
 - ◆ Vertebral artery occlusions are managed with anticoagulation, if it is not contraindicated.
 - ◆ Endovascular embolization is an option if injury is not accessible by standard exposure.
 - ◆ **Exposure usually requires rongeur to open vertebral foramen; temporary occlusion with bone wax can be helpful.**
- **Jugular vein.**
 - Recommendations: Ligation or selective repair.
 - Utility of temporary vascular shunts: None.
 - Method/conduit: Lateral venorrhaphy, vein patch, or saphenous vein.

- Pearls:
 - ◆ Significant jugular vein injuries can be ligated without adverse effects.
 - ◆ Repair of jugular injuries should be considered in the setting of traumatic brain injury with elevated intracranial pressure.
- **Large vein injuries.**
 - Pearls:
 - ◆ Initial control can be accomplished by one or more fingers on the bleeding segment.
 - ◆ **Use of clamps for control may injure the vein further.**
 - ◆ Avoid too small of a needle and suture, which are difficult to maneuver in blood. 4-0 PROLENE on an SH-tapered needle is a substantive suture on a needle large enough to see.
 - ◆ Manual direct pressure can be replaced with a small sponge stick or Kittner.
 - ◆ Hemorrhage control with ligation is preferable to patency with death from exsanguination.
 - ◆ **Be wary of risk of air embolism with large vein injuries.**
- **Ligation of vessels.**
 - Pearls:
 - ◆ Acceptable damage control maneuver, especially for small, more distal arteries and veins (Table 25-1).

Table 25-1. Vessels Amenable to Ligation

Veins That Can Be Ligated Routinely	Arteries That Can Be Ligated Routinely
Internal/external jugular	Digital
Brachiocephalic	Radial or ulnar, but not both; preserve ulnar when possible
Infrarenal inferior vena cava	External carotid
Left renal	Brachial distal to profundi and adequate wrist; Doppler signal
Internal iliac	Subclavian branches
Subclavian	Internal iliacs
Mesenteric	Profunda femoris
Tibialis	Hepatic

- ◆ Temporary vascular shunting to restore perfusion should be considered before ligation.
- ◆ Continuous wave Doppler should be checked before arterial ligation to judge perfusion/ viability.
- **Fogarty thrombectomy catheters.**
 - Pearls:
 - ◆ Sized at 2–7 Fr catheters; maximum balloon diameter of the 2 and 3 Fr catheters is 4 and 5 mm, respectively.
 - ◆ Inflate with saline using a 1 cc tuberculin syringe (0.2–0.75 cc) while withdrawing from the vessel.
 - ◆ Goal is clot, not intima, removal; so, do not overinflate or “drag” too much.
 - ◆ May be used to control bleeding with use of a three-way stopcock to maintain inflation.
 - ◆ Proximal and distal thrombectomies should be performed prior to performing repair.
- **Temporary vascular shunts.**
 - Pearls:
 - ◆ Inline shunts rest in the vessel (“in situ”), whereas long external shunts are designed to loop.
 - ◆ Inline Argyl shunts come in a cylinder container with sizes 8, 10, 12, and 14 Fr Fogarty catheters.
 - ◆ Inline Javid shunts are longer and individually packaged.
 - ◆ Sundt shunts are designed with short (15 cm; inline) and long (30 cm; external) profiles.
 - ◆ Equal success has been had with Argyl, Javid, and Sundt shunts without systemic anticoagulation.
 - ◆ Secured with silk ligatures and patent for up to 6 hours; reports of longer duration exist.
 - ◆ Shunts should be removed with formal repair in-theater prior to AIR EVAC to Role 4.
 - ◆ Temporary vascular shunts are effective and should be considered in the management of nearly all extremity vascular injury patterns, including proximal venous injuries. Their main advantage is provision of early restoration of flow and mitigation of the damaging effects of arterial ischemia and venous hypertension. As an abbreviated procedure, compared with formal vascular repair, shunting extends the window of opportunity for limb salvage

in some patterns of vascular injury. Although the patency at 3–4 hours is higher in larger, more proximal vessels (axillary/brachial and femoral/popliteal), shunts have been used effectively in smaller (distal brachial/forearm and tibial) vessels. Outcomes of extremity vascular injury managed with temporary shunts have been recorded, demonstrating no adverse effect of this technique and a limb salvage advantage in the most severely injured limbs (Mangled Extremity Severity Score [MESS] ≥ 8).

- ◆ **Consider distal fasciotomies.**

- **Pediatric vascular injuries.**

- Pearls:

- ◆ Less than 10 years old: intervention should be avoided in those given a propensity for spasm.
- ◆ Ligation is more well tolerated in infants and toddlers, given the ability to recruit collaterals.
- ◆ Perform interrupted suture lines (6-0 PROLENE) to allow expansion with growth of the child

- **Endovascular capability and inferior vena cava filters.**

- Pearls:

- ◆ Techniques should be used in a small subset of injuries and directed in consultation with a trauma surgeon.
- ◆ Placement of vena cava filters should be considered in patients who have contraindications for anticoagulation.

- **Use of prosthetic graft material.**

- Pearls:

- ◆ ePTFE (GORE-TEX) or Dacron used for central torso vascular injuries (aorta, great vessels).
- ◆ Prosthetic conduit acceptable as a last resort in extremities when vein cannot be harvested.
- ◆ If prosthetic used in extremity injury, notify higher levels of care to facilitate surveillance.

- **Harvesting and use of autologous vein.**

- Pearls:

- ◆ If possible, use reversed greater saphenous vein from the uninjured extremity.
- ◆ Expose at saphenofemoral junction or anterior to medial malleolus (consistent locations). Be sure to mark anatomically distal end as “inflow,” ensuring reversal of vein conduit.

- ◆ Introduce 18-gauge plastic vein or metallic olive tip cannula to distend with heparin saline.
- ◆ Nearly always in the setting of trauma, the vein appears in situ as “too small” or “not adequate” due to vasoconstriction or spasm. Best assessed after hydrodistention.
- **Soft-tissue coverage and anastomotic disruption.**
 - Pearls:
 - ◆ Cover vascular repairs with available, viable local tissue (muscle and adipose).
 - ◆ If no soft tissue to cover, route grafts out of the zone of injury.
 - ◆ Poorly covered vascular anastomosis can “blow out.”
 - ◆ Avoid direct placement of negative pressure wound therapy sponge on vascular structures.

If no tissue is available to cover the vascular repair, route an interposition graft out of the zone of injury through another myocutaneous or even subcutaneous path.

- **Anticoagulation.**
 - Pearls:
 - ◆ Heparin saline is typically 1,000 U/1 L, although other mixtures with or without papaverine (60 mg/1 L) are acceptable.
 - ◆ Systemic anticoagulation is achieved with 50 U/kg of IV heparin with 1,000 units repeated at 1 hour. Repeat doses are not recommended, given the propensity for bleeding in wartime injury.
 - ◆ “Regional anticoagulation” is the use of heparin saline flush in the inflow/outflow vessels.
- **Post-op care.**
 - Palpable pulses obtained in the operating room should remain palpable post-op.
 - Pulse changes, even if Doppler signals remain, may indicate graft thrombosis and should be investigated.
 - Consider low-dose heparin as deep vein thrombosis prophylaxis.

- Use with caution in multiply injured and head-injured patients.
- Slight elevation of injured extremity improves post-op edema.

For Clinical Practice Guidelines, go to
[http://usaisr.amedd.army.mil/clinical_practice_
guidelines.html](http://usaisr.amedd.army.mil/clinical_practice_guidelines.html)

